

## Technical Note

## Surgical Technique for Chronic Proximal Patellar Tendinopathy (Jumper's Knee)

Alfredo Marques Villardi, M.D., M.Sc., Ph.D.,  
 João Gabriel de Cerqueira Campos Villardi, M.D., M.Sc., Rafael Erthal de Paula, M.D.,  
 Tiago Carminatti, M.D., and Raphael Serra Cruz, M.D.

**Abstract:** Chronic proximal patellar tendinopathy is a challenging condition for its troublesome management in the active patient and difficulty in defining the failure of conservative treatment to indicate surgery. Usually, patients with chronic proximal patellar tendinopathy have already tried several physiotherapeutic modalities and are away from their preferred physical activities for variable periods. The current literature presents some open and even arthroscopic options for treating recalcitrant patellar tendinopathy using a variable magnitude of resources and costs. The purpose of this article was to depict a very simple and inexpensive surgical option for treating this condition, which can be applied worldwide.

Patellar tendinitis is the most common tendinopathy of the knee's extensor mechanism.<sup>1</sup> Its typical location is at the proximal aspect of the tendon, where it inserts into the distal pole of the patella (near the joint line).<sup>1,2</sup> Although patellar tendinopathy can be observed in both patients of both sexes and at all ages, it is a disease that usually affects active male patients younger than 40 years, being directly correlated with the physical activity performed.<sup>3-5</sup> It can even occur during adolescence<sup>6</sup> and has a high prevalence in young elite soccer players compared with participants in less explosive sports, especially at the ages of 15 to 17 years.<sup>7</sup>

Patellar tendinopathy is also referred as "jumper's knee"<sup>8-10</sup> because of its relation with sports that require strenuous jumping<sup>11</sup> and is included in the wide range of diagnoses known as "anterior knee pain."<sup>3</sup> Its clinical

features are mainly characterized by pain and limitation of the knee's active extension, impacting not only sports but also work performance.<sup>12</sup> The onset of the disease may be characterized as acute or chronic and traumatic or due to a local degenerating process, which are the cases indicated for the proposed treatment. Some risk factors may contribute to the onset of jumper's knee in elite-level male volleyball players, such as vertical jump, ankle dorsiflexion range, dynamic balance, dynamic knee alignment, and landing mechanics.<sup>13</sup>

Although the diagnosis of chronic proximal patellar tendinopathy (CPPT) is essentially clinical, imaging examinations may help in the evaluation of secondary factors, such as infrapatellar osteophytes and patellar height<sup>14</sup> on lateral radiographs, as well as tissue quality and tendon integrity on ultrasound and nuclear magnetic resonance imaging, which is the gold standard for this investigation.<sup>4,10</sup> Potential differential diagnoses include Osgood-Schlatter disease and its sequelae, patellofemoral chondropathy or arthrosis, and pathologic synovial plica.

In 1973, Blazina<sup>9</sup> proposed the currently most used classification for this pathology. It is divided into 4 progressive stages and correlates the onset of pain with the moment of physical activity, as follows: stage I, pain after exercise; stage II, pain at the beginning of sports activity, disappearing with warm-up and possibly reappearing with fatigue; stage III, pain at rest and during activity; and stage IV, rupture of the patellar tendon.

Usually, the treatment of CPPT is conservative, based on rest and physiotherapy. Surgical treatment is

From Hospital São Vicente de Paulo (A.M.V., J.G.d.C.C.V., R.E.d.P., T.C., R.S.C.); Instituto Nacional de Traumatologia e Ortopedia Jamil Haddad—MS/INTO (A.M.V., R.E.d.P., R.S.C.); Hospital Federal da Lagoa (T.C.); and Instituto Brasil de Tecnologias da Saúde (R.S.C.), Rio de Janeiro, Brazil.

The authors report that they have no conflicts of interest in the authorship and publication of this article. Full ICMJE author disclosure forms are available for this article online, as [supplementary material](#).

Received May 14, 2019; accepted July 18, 2019.

Address correspondence to Raphael Serra Cruz, M.D., Hospital São Vicente de Paulo, Rua Doutor Satamini, 333, Tijuca, Rio de Janeiro, Brazil. E-mail: [dr.serracruz@gmail.com](mailto:dr.serracruz@gmail.com)

© 2019 by the Arthroscopy Association of North America. Published by Elsevier. This is an open access article under the CC BY-NC-ND license (<http://creativecommons.org/licenses/by-nc-nd/4.0/>).

2212-6287/19649

<https://doi.org/10.1016/j.eats.2019.07.013>

**Table 1.** Indications and Contraindications for Procedure

## Indications

- Failure of conservative treatment for 3-6 mo
- Blazina stages III and IV
- Enthesophyte in friction with patellar tendon

## Contraindications

- Small patellar tendon width (<25 mm)
- Total thickness or diffuse tendon involvement
- Lack of compliance with rehabilitation protocol

indicated after the failure of conservative management (stages I-III) or in cases of rupture (stage IV). A summary of indications and contraindications for the described procedure is found in [Table 1](#). Over the years, several surgical techniques have been described: from minimally invasive (arthroscopic) to open surgery, either with or without resection of the distal pole of the patella and/or microvascular reinforcement.<sup>15</sup>

The aim of the proposed surgical procedure is to remove the diseased portion of the tendon along with the area of enthesopathy at the distal pole of the patella, as well as possible enthesophytes, leaving a healthy bone bed. The final goal is to improve symptoms and provide a safe return to sports activities in patients with CPPT, without recurrence. This article describes a very simple surgical technique that can reproducibly achieve these goals at a low cost.

## Surgical Technique

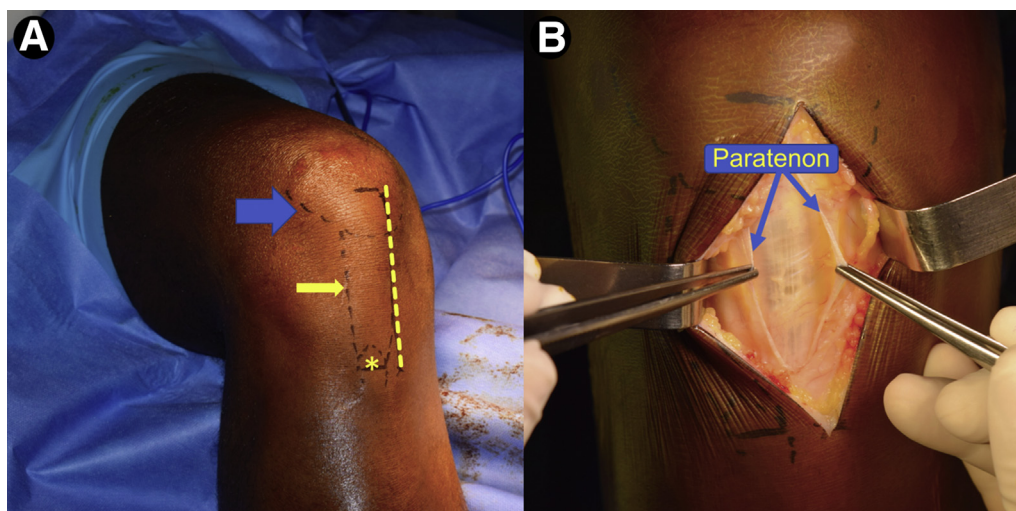
### Patient Positioning

After receiving spinal anesthesia, the patient is positioned supine on the operating table with the operating limb hanging beside it. To prevent the patient from falling, the use of a safety belt and a pelvic support is

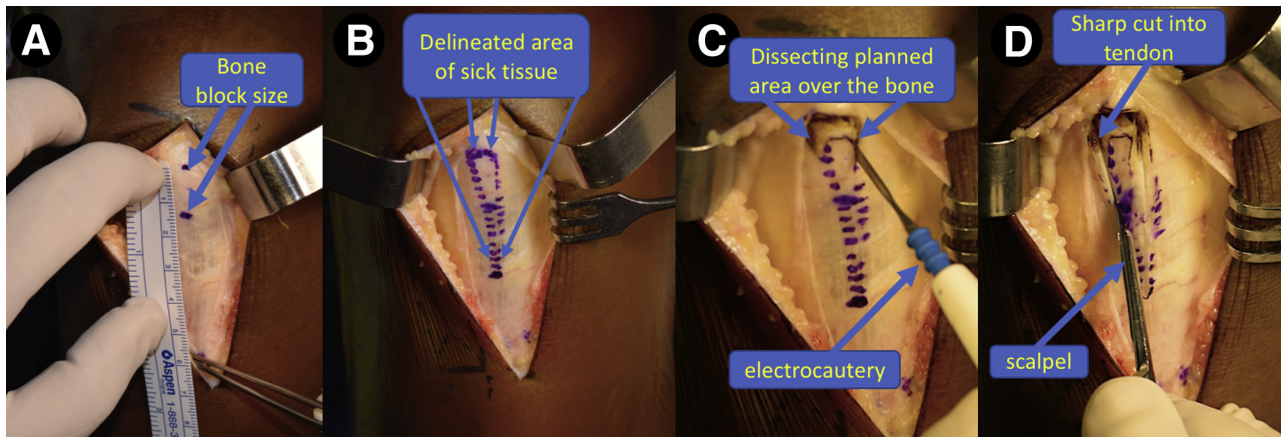
recommended. A cushion is placed under the thigh to keep the knee bent at 90° of flexion during the operation. A well-padded tourniquet is placed high on the thigh. The limb is then properly prepared and draped for a sterile technique. Before exsanguinating the surgical limb and inflating the tourniquet, the surgeon draws the main anatomic landmarks: patella, patellar tendon, and tibial tuberosity ([Fig 1A](#)).

### Surgical Approach

A skin incision is planned at the anterior aspect of the knee, along the medial border of the patellar tendon, extending from 2 cm above the distal pole of the patella to a place immediately medial to the tibial tuberosity. This medialization of the skin incision prevents the future scar from being in direct contact with rigid surfaces when the patient is on his or her knees. The paratenon is then sharply opened and carefully dissected medially and laterally ([Fig 1B](#)). It is advisable to preserve the paratenon for adequate closure at the end of the procedure because it is important to the healing process. The proximal and distal borders of the patellar tendon are identified and marked with a surgical pen ([Video 1](#)). A 1.5-cm distance is marked proximally to the distal pole of the patella ([Fig 2A](#)), and the area to be excised (based on magnetic resonance imaging) is drawn over the tendon as triangle, converging at its distal insertion ([Fig 2B](#)). An electrocautery device is used to dissect the previously marked area over the patella to facilitate the cut by the saw ([Fig 2C](#)). During the excision of the diseased area, it is important to maintain the knee bent at 90° of flexion to keep adequate tension on the structures. According to the previously marked area, a sharp incision is then



**Fig 1.** First steps of surgical procedure for treating chronic proximal patellar tendinopathy in a right knee. (A) Anatomic landmarks drawn on skin before incision: contour of patella (blue arrow), contour of patellar tendon (yellow arrow), tibial tuberosity (asterisk), and planned skin incision (dashed line). (B) Dissected paratenon (held by tweezers) after anterior skin incision and subcutaneous tissue dissection.



**Fig 2.** Planning of excision of diseased tissue in a right knee after dissection of paratenon. (A) A distance 15 mm from the inferior pole of the patella is marked. (B) The entire area of diseased tissue is delineated as a triangle with the base facing upward. (C) Dissection of the planned area over the patella is performed with an electrocautery device to facilitate the following cut by the saw. (D) The planned area in the tendon is cut with a No. 23 scalpel.

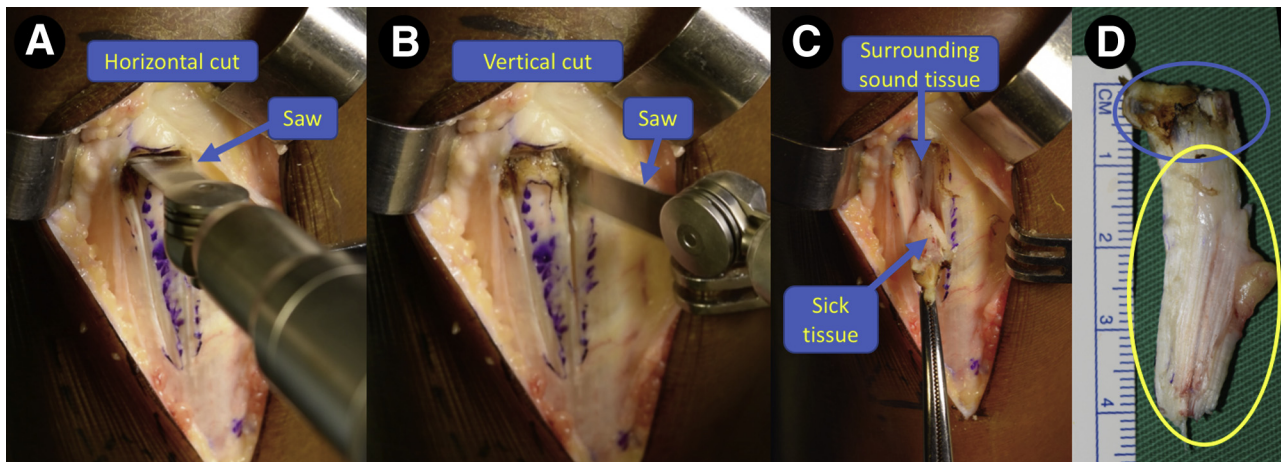
made along the patellar tendon using a regular scalpel (Fig 2D) to avoid a thermal lesion in the healing borders that could be caused by electrocautery.

Similarly to bone-tendon-bone harvest for anterior cruciate ligament reconstruction, an oscillating saw is used to remove part of the distal patellar bone where the diseased tendon inserts. The upper portion of the bone cut is performed with the saw perpendicular to the surface of the patella in a horizontal fashion (Fig 3A). Care must be taken to avoid over-penetration of the saw because this may damage the articular cartilage. The lateral and medial parts of the bone cut are made with a slight inclination of the saw (Fig 3B) to create a triangular bone block, reducing the risk of iatrogenic patellar fracture. The small bone block is then removed along with the unsound tissue (Fig 3 C and D).

After removal of the fragment, a small rongeur is used to clean this region and let sound bone to be in contact with the remaining healthy patellar tendon (Fig 4A). A small curette is also used to clear the area, which is then washed with saline solution before closure. The gap in the tendon is left open, and the previously dissected paratenon is closed with No. 3-0 Vicryl sutures (Ethicon, Somerville, NJ) (Fig 4B). The subcutaneous tissue and skin are closed in a regular fashion, and the procedure is complete. The main pearls and pitfalls for this technique are summarized in Table 2.

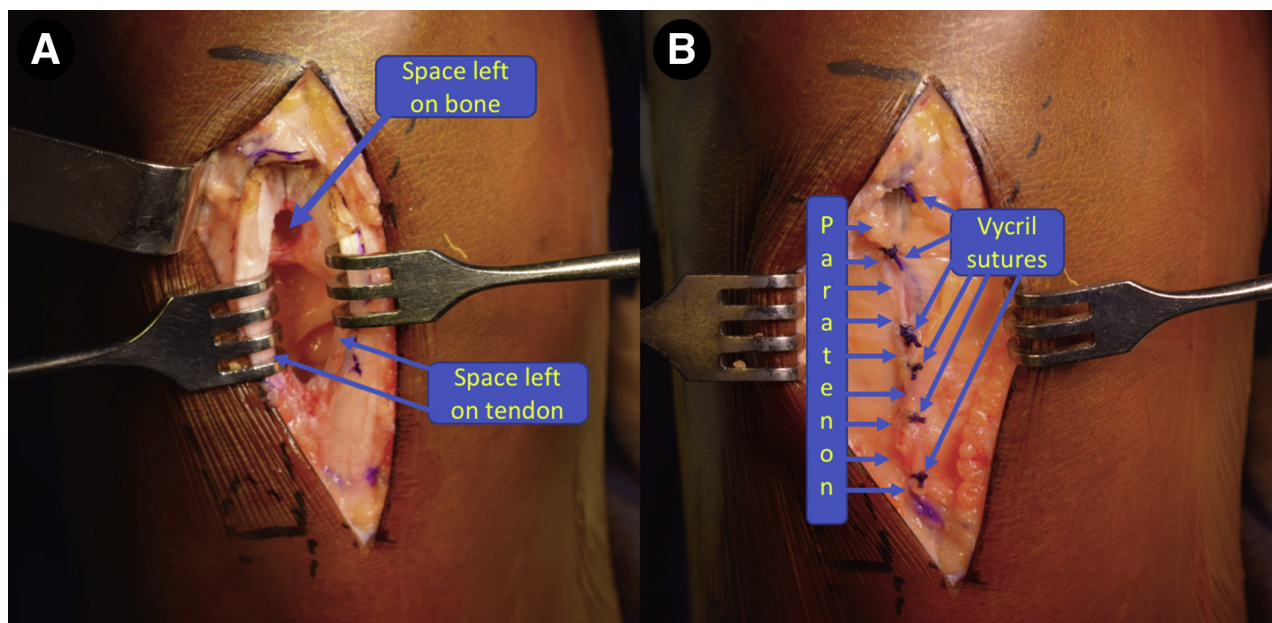
### Rehabilitation

The initial rehabilitation protocol used is similar to the postoperative protocol for anterior cruciate ligament reconstruction using patellar tendon graft. There is no



**Fig 3.** Excision of diseased tissue in a right knee. (A) Superior bone cut on the patella with the saw perpendicular to the bone. (B) Side bone cut at the planned area. One should observe a slight inclination of the saw to create a triangular bone block, avoiding iatrogenic patellar fracture. (C) Removal of the diseased tissue after excision of the bone block. (D) Macroscopic aspect of excised tissue. The blue ellipse marks the bony fragment, and the yellow ellipse marks the tendinous part.





**Fig 4.** Final aspect of surgery in a right knee. (A) Deep layers showing healthy tissues after removal of the diseased area and washout with saline solution. (B) Closure of paratenon.

need for a knee brace. Partial weight bearing is allowed immediately with crutches, the use of which is weaned off as soon as the patient recovers neuromuscular control of the quadriceps and regains confidence. This typically happens by week 2.

Physical therapy is started early, including exercises to improve range of motion, reduce pain and edema, and promote quadriceps activation. After 8 to 12 weeks, proprioceptive, functional exercises and strength training are progressively performed, as previous goals are achieved. Activities involving squatting, jumping, and sprinting are avoided for the first 4 months post-operatively. After gaining sufficient strength and balance, the patient is allowed to return to normal activities. To avoid the recurrence of symptoms, it is extremely important to reassess and correct possible imbalances between the extensor and flexor muscles, stretch shortened muscle groups, adjust the physical workload, and develop appropriate proprioception and

sports gestures, before effectively returning to sports activity.

## Discussion

The current literature presents a few controversies regarding the surgical indications for the treatment of CPPT.<sup>16</sup> Our approach is best indicated in patients classified as having Blazina stage I to III pathology after failure of conservative treatment or in patients who already present with a rupture of the tendon (Blazina stage IV).<sup>9</sup> On the other hand, the surgical technique to be chosen is debatable. The surgical options found in the literature differs regarding the surgical approach (traditional open access or minimally invasive arthroscopic technique)<sup>17-21</sup>; whether to perform resection of the distal pole of the patella<sup>22</sup>; whether to perform longitudinal incisions through the tendon<sup>3</sup>; whether to perform closure of the paratenon<sup>3</sup>; and whether to use biological enhancers, such as platelet-rich plasma.<sup>23</sup>

## Table 2. Pearls and Pitfalls

### Pearls

- The knee should be held at 90° during excision of the damaged area to keep adequate tension on the patellar tendon.
- The sick area should be indentified on an MRI scan obtained earlier to make sure it is included in the resection.
- After using the saw, the removal of the bone block may be finished with a small and sharp osteotome but leverage should not be created.
- To avoid reduction of the tendon's width during the healing process, the paratenon should not be closed too tightly.

### Pitfalls

- Excising more than one-third of the tendon increases the risk of iatrogenic rupture of the patellar tendon.
- Going too deep with the bone cut increases the risk of patellar fracture and damage to the cartilage. A graded saw should be used, with a mark at 10 mm.
- Extending the bone cut over the previously delineated area may increase the risk of patellar fracture.
- A delay in rehabilitation may impair the gain in range of motion.

MRI, magnetic resonance imaging.

**Table 3.** Advantages and Disadvantages

Advantages
Low cost
Reproducibility
Low morbidity
No need for adjuvant techniques
Disadvantages and limitations
Open technique
Necessity for early rehabilitation
Inadequate for patients with narrow patellar tendon
Risk of patellar fracture

This article describes an open technique with anterior longitudinal skin access, careful deep-layer dissection, and excision of the pathologic and symptomatic area, which comprises the proximal patellar tendon tissue and the patellar bone apex, with reliable postoperative results and reduced morbidity. The advantages and disadvantages of this technique are listed in Table 3.

Minimally invasive arthroscopic techniques<sup>18,24</sup> have been advocated as superior to open surgery, considering the postoperative clinical results and return-to-sport rates.<sup>3</sup> However, a recent systematic review has shown no statistically significant difference regarding the same parameters, both being effective in the treatment of CPPT.<sup>25</sup>

Resection of the patellar apex is also a target of discussion, with better results being shown in some studies<sup>15,18,26</sup> but not others<sup>22</sup> by associating this procedure. Altogether, it is important to consider that when the patella has an elongated distal pole, this might be a more precise indication for excision, but this topic still demands more comparative studies. Drilling of the distal patellar apex as introduced by Smillie<sup>27</sup> is also an option to be considered with the intention of promoting the supply of mesenchymal cells and stimulating tissue repair.<sup>26-28</sup> With the same goal, some authors have advocated performing longitudinal incisions through the patellar tendon<sup>29</sup> or using platelet-rich plasma as a biological enhancer.<sup>23,30</sup> It is valuable to ponder that surgical results not only are related to the chosen technique but also depend on a wide range of factors such as the correct surgical indication, surgeon skill, and the postoperative rehabilitation program.<sup>18,19,29,31</sup>

The present surgical description represents an easy and effective technique with high reproducibility because it is very similar to a patellar tendon graft harvest. No adjuvant reinforcement procedure is required, which guarantees less local morbidity compared with other techniques. Because the technique does not require any surgical implants, it is also an inexpensive solution, allowing it to be used even in places with fewer financial resources. For those reasons, it should be considered a simple option in the arsenal of procedures developed for the treatment of CPPT.

## Acknowledgment

The authors acknowledge Dr. Roberta Acar for the histologic analysis of the unsound tendon removed in our surgical procedure.

## References

1. Ferretti A, Conteduca F, Camerucci E, Morelli F. Patellar tendinosis: A follow-up study of surgical treatment. *J Bone Joint Surg Am* 2002;84:2179-2185.
2. Witvrouw E, Bellemans J, Lysens R, Danneels L, Cambier D. Intrinsic risk factors for the development of patellar tendinitis in an athletic population: A two-year prospective study. *Am J Sports Med* 2001;29:190-195.
3. Brockmeyer M, Diehl N, Schmitt C, Kohn DM, Lorbach O. Results of surgical treatment of chronic patellar tendinosis (jumper's knee): A systematic review of the literature. *Arthroscopy* 2015;31:2424-2429.e3.
4. Via AG, Papa G, Oliva F, Maffulli N. Tendinopathy. *Curr Phys Med Rehabil Rep* 2016;4:50-55.
5. Maffulli N, Giai Via A, Oliva F. Revision surgery for failed patellar tendinopathy exploration. *Sports Med Arthrosc* 2017;25:36-40.
6. Rudavsky A, Cook JL, Docking S. Proximal patellar tendon pathology can develop during adolescence in young ballet dancers—a 2-year longitudinal study. *Scand J Med Sci Sports* 2018;28:2035-2041.
7. Bode G, Hammer T, Karvouniaris N, et al. Patellar tendinopathy in young elite soccer—clinical and sonographical analysis of a German elite soccer academy. *BMC Musculoskelet Disord* 2017;18:344.
8. Roels J, Martens M, Mulier JC, Burssens A. Patellar tendinitis (jumper's knee). *Am J Sports Med* 1978;6:362-368.
9. Blazina ME. Jumper's knee. *Orthop Clin North Am* 1973;4:665-678.
10. Shalaby M, Almekinders LC. Patellar tendinitis: The significance of magnetic resonance imaging findings. *Am J Sports Med* 1999;27:345-349.
11. Santana JA, Sherman AL. *Jumpers knee*. Treasure Island, FL: StatPearls, 2019.
12. De Vries AJ, Koolhaas W, Zwerver J, et al. The impact of patellar tendinopathy on sports and work performance in active athletes. *Res Sports Med* 2017;25:253-265.
13. MacDonald K, Palacios-Derflingher L, Kenny S, Emery C, Meeuwisse WH. Jumper's knee: A prospective evaluation of risk factors in volleyball players using a novel measure of injury [published online October 19, 2018]. *Clin J Sport Med*, <https://doi.org/10.1097/JSM.0000000000000638>.
14. Dan MJ, McMahon J, Parr WCH, et al. Evaluation of intrinsic biomechanical risk factors in patellar tendinopathy: A retrospective radiographic case-control series. *Orthop J Sport Med* 2018;6: 2325967118816038.
15. Kaeding CC, Pedroza AD, Powers BC. Surgical treatment of chronic patellar tendinosis: A systematic review. *Clin Orthop Relat Res* 2007;455:102-106.
16. Maier MW, Niklasch M, Dreher T, et al. Proprioception 3 years after shoulder arthroplasty in 3D motion analysis: A prospective study. *Arch Orthop Trauma Surg* 2012;132:1003-1010.

17. Coleman BD, Khan KM, Kiss ZS, Bartlett J, Young DA, Wark JD. Open and arthroscopic patellar tenotomy for chronic patellar tendinopathy. A retrospective outcome study. Victorian Institute of Sport Tendon Study Group. *Am J Sports Med* 2000;28:183-190.
18. Lorbach O, Diamantopoulos A, Paessler HH. Arthroscopic resection of the lower patellar pole in patients with chronic patellar tendinosis. *Arthroscopy* 2008;24:167-173.
19. Ogon P, Maier D, Jaeger A, Suedkamp NP. Arthroscopic patellar release for the treatment of chronic patellar tendinopathy. *Arthroscopy* 2006;22:462.e1-462.e5.
20. Pestka JM, Lang G, Maier D, Sudkamp NP, Ogon P, Izadpanah K. Arthroscopic patellar release allows timely return to performance in professional and amateur athletes with chronic patellar tendinopathy. *Knee Surg Sports Traumatol Arthrosc* 2018;26:3553-3559.
21. Lang G, Pestka JM, Maier D, Izadpanah K, Sudkamp N, Ogon P. Arthroscopic patellar release for treatment of chronic symptomatic patellar tendinopathy: Long-term outcome and influential factors in an athletic population. *BMC Musculoskelet Disord* 2017;18:486.
22. Maier D, Bornebusch L, Salzmann GM, Sudkamp NP, Ogon P. Mid- and long-term efficacy of the arthroscopic patellar release for treatment of patellar tendinopathy unresponsive to nonoperative management. *Arthroscopy* 2013;29:1338-1345.
23. Kruckeberg BM, Chahla J, Ferrari MB, Sanchez G, Moatshe G, LaPrade RF. Open patellar tendon tenotomy, debridement, and repair technique augmented with platelet-rich plasma for recalcitrant patellar tendinopathy. *Arthrosc Tech* 2017;6:e447-e453.
24. Romeo AA, Larson RV. Arthroscopic treatment of infra-patellar tendonitis. *Arthroscopy* 1999;15:341-345.
25. Marcheggiani Muccioli GM, Zaffagnini S, Tsapralis K, et al. Open versus arthroscopic surgical treatment of chronic proximal patellar tendinopathy. A systematic review. *Knee Surg Sports Traumatol Arthrosc* 2013;21:351-357.
26. Griffiths GP, Selesnick FH. Operative treatment and arthroscopic findings in chronic patellar tendinitis. *Arthroscopy* 1998;14:836-839.
27. Smillie IS. *Injuries of the knee joint*. Edinburgh: E & S Livingstone, 1962.
28. Popp JE, Yu JS, Kaeding CC. Recalcitrant patellar tendinitis. Magnetic resonance imaging, histologic evaluation, and surgical treatment. *Am J Sports Med* 1997;25:218-222.
29. Shelbourne KD, Henne TD, Gray T. Recalcitrant patellar tendinosis in elite athletes: Surgical treatment in conjunction with aggressive postoperative rehabilitation. *Am J Sports Med* 2006;34:1141-1146.
30. Andriolo L, Altamura SA, Reale D, Candrian C, Zaffagnini S, Filardo G. Nonsurgical treatments of patellar tendinopathy: Multiple injections of platelet-rich plasma are a suitable option: A systematic review and meta-analysis. *Am J Sports Med* 2019;47:1001-1018.
31. Verheyden F, Geens G, Nelen G. Jumper's knee: Results of surgical treatment. *Acta Orthop Belg* 1997;63:102-105.